

AXIAL MUSCLES OF HEAD

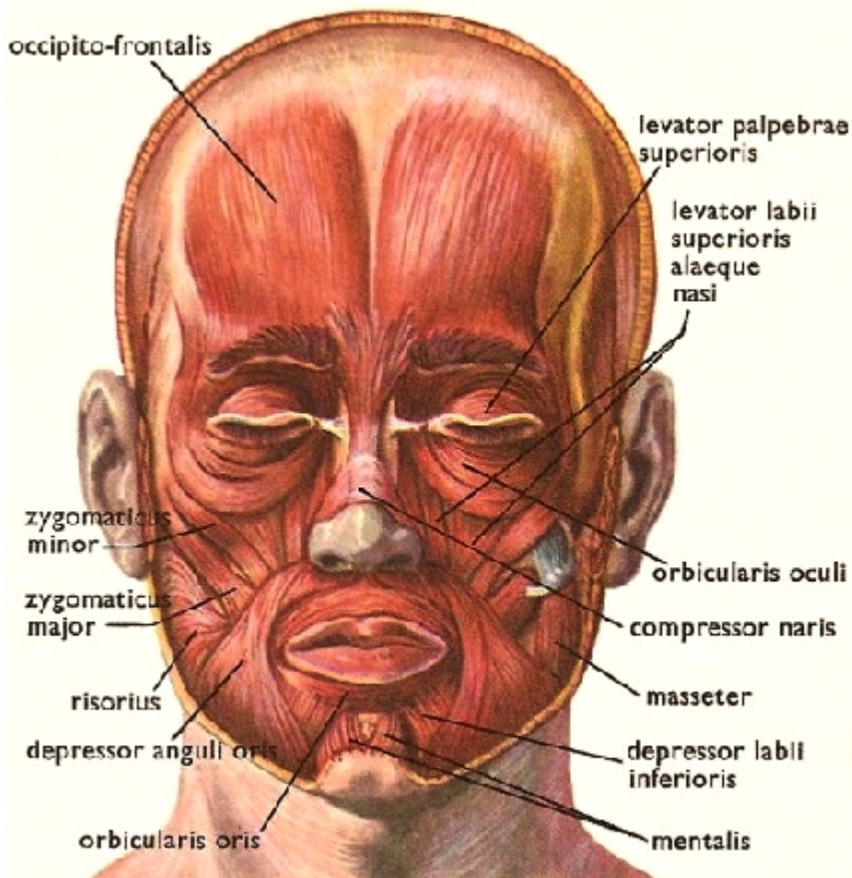
11/19/81, rvsd 2 Dec 1999, 21 Nov 01, 17 Nov 03, 19Nov07, 17Nov08, 16Nov09, 15Nov10, 14Nov11
 S&M, p. 209, Martini 5th, 320-335, KapIt and Elson: pl 27-26, Martini 6th: 340-357, Martini 7th: 334-349, 8th: 341-358

600 muscles in body, named for:

shape location action attachments
 divisions number relationship size

HEAD AND NECK: (p 333) facial muscles move skin, not bone, facial expression. arise fr bone or superficial fascia, insert into skin

- orbicularis oculi** [rut, little, of the eye]
 sphincter around eye, winks, squints, closes
- orbicularis oris** [rut, little, of the mouth]
 closes mouth, purses lips
- epicranii:** moves scalp. two parts:
frontalis
occipitalis attach to galea aponeurotica,
- corrugator** [together, fold]
 draws eyebrows together, frown procerus
 wrinkles skin between eyebrows
- mentalis** [of the chin]
 pouting muscle
- risorius** [laughter]
 draws mouth laterally
- zygomaticus major & minor** [join]
 raise angle of mouth, smiling
- platysma** [flat] (p 348)
 superficial muscle of neck, orig in fascia of deltoid & pectoralis
 tightens neck, depresses mandible



MASTICATION: (p336, 337)

- temporalis** **origin** frontal, temporal, parietal
insertion coronoid process and mandibular ramus (near articulation with mandibular fossa) fan shaped
- masseter** [chew] **origin:** zygomatic arch
insertion: angle and ramus of mandible
- pterygoid, lateral and medial:** positions jaw, side wise grinding, protrusion of jaw
- buccinator** [cheek] positions food for chewing

Tongue: many have "gloss-" on name: **intrinsic** (shape of tongue) and **extrinsic** (movement of tongue)

THROAT: (p 333, under platysma)

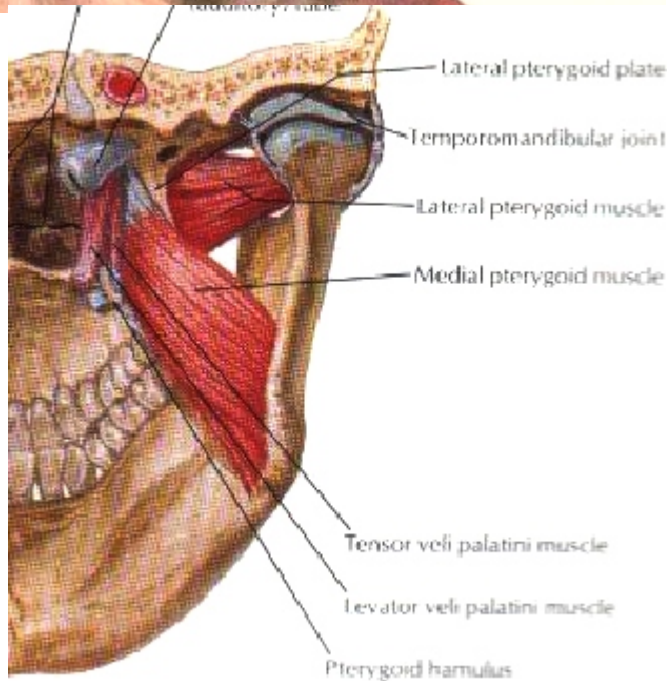
- sternocleidomastoid** **origin:** manub & clavicle
insertion: mastoid process. major muscle of neck, marks anterior, posterior triangles of neck,

Anterior triangle of neck deep muscles move the hyoid bone:
 suprahyoid attaches to styloid process, mandible, inserts into hyoid, moves up during swallowing
 infrahyoid attach to manubrium, clavicle, thyroid cartilage of larynx, etc, pull down on hyoid and larynx following swallowing

Posterior triangle of neck: posterior border: **trapezius**, lower: **clavicle**, front: **sternocleidomastoid**.

- Scalenes fr top 2 ribs to transverse process of cerv. vert
- splenius capitis** "bandage muscle," holds down deeper muscles of neck (p 340, 349)
- insert** mastoid process, occipital and transverse proc of 1st 3 cerv vert.
- origin** upper thoracic spinous processes, **7th cerv vert**

and ligamentum nuchae: [back of the neck] sail-like ligament, attach to midline of occipital and spines of cervical vertebra. anchors many post neck muscles, inhibits neck fr flexion



Lateral Neck Muscles

