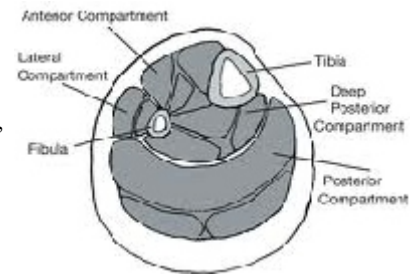


MUSCLES ACTING ON THE ANKLE AND FOOT

David B. Fankhauser, PhD

Martini's 6th, pp 367-377, 7th: 363-372, 8th: 371-383, 9th: 367-367

1Dec81, rvsd 5Dec96, 4Dec97, 2Dec99, 27Nov00, 28Nov01, 4Dec02, 26 Nov 03, 1 Dec 03, 21 Nov 05, 28Nov07, 1 Dec08, 30Nov09, 29Nov10, 30Nov11



left leg:

THREE COMPARTMENTS OF THE LEG: (p 365)

ANTERIOR COMPARTMENT: dorsiflex foot, extends toes.

tendons of insertion are held down by two retinacula at ankle

tibialis anterior	insertn: medial cuneiform, 1st metatarsal	dorsiflex, invert (small tears = shin splints)
extensor digitorum longus	insertn: superior surf of phalanges 2-5	extends toes 2-5, everts foot
extensor hallucis longus	insertn: superior surf dist 1 st phalanx	extends great toe, inverts foot

LATERAL COMPARTMENT: everts foot. (Very small compartment)

fibularis (peroneus) longus	insertn: 1st metatarsal, med cuneiform (tendon <i>under</i> foot)	evert foot, plantar flex
fibularis (peroneus) brevis	insertn: lateral side of 5th metatarsal	evert foot, plantar flex

POSTERIOR COMPARTMENT, SUPERFICIAL: all but last plantar flex foot

gastrocnemius	origin: lateral and medial condyles of femur	insertn: Achilles tendon	plantar flex
soleus	origin: fibula and tibia	insertn: Achilles tendon	plantar flex
plantaris	origin: post. surf femur, above lateral condyle	insertn: posterior calcaneus	plantar flex
popliteus	origin: lat. condyle femur	insertn: post tibia	pl.flex, med rotates leg

POSTERIOR, DEEP: These internal muscles have tendons which pass behind medial malleolus, act on foot and toes

flexor hallucis longus	origin: fibula	insertn: <i>distal</i> 1st phalanx	flexes big toe, plantar flex foot, inverts foot
flexor digitorum longus	origin: tibia	insertn: <i>distal</i> phalanges 2-5	plantar flexes toes 2-5
tibialis posterior	origin: tibia, fibula	insertn: medial tarsals, 2nd-4th metatarsals	inversion, dorsiflexion

INTRINSIC MUSCLES OF FOOT: (p 367) similar to hand, but heavier.

The foot possesses supporting arch. Covered with plantar aponeurosis

DORSAL (extensors):

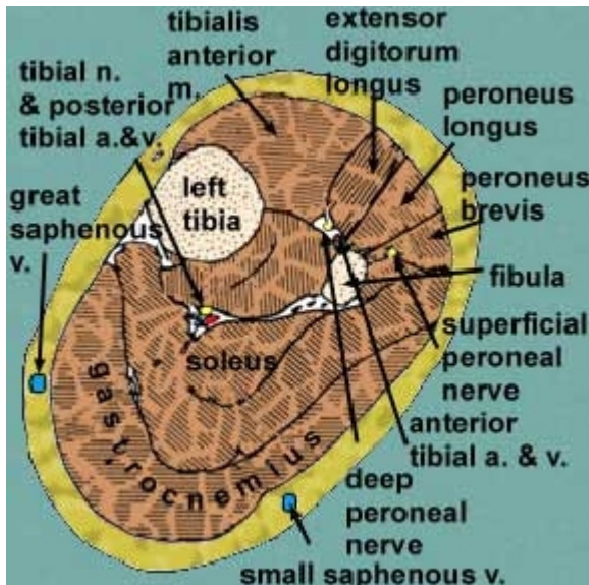
extensor hallucis brevis	origin: calcaneous	insertn: 1 st prox phalanx
extensor digitorum brevis	origin: calcaneous	insertn: 2, 3, 4th prox phalanx, tendons of ext. dig. longus

PLANTAR four layers:

flexor digitorum brevis	origin: calcaneous	insertn: middle phalanges, 2-5 split tendons for "longus"
--------------------------------	--------------------	---

Most superficial (step on a stone, bruised: = "stone bruise")

abductor digiti minimi	superficial
lumbricales	second layer
adductor hallucis	third layer
plantar interossei	deepest layer



Front View of Foot Muscles

